

## True Memory, False Memory, and Subjective Recollection Deficits After Focal Parietal Lobe Lesions

David B. Drowos and Marian Berryhill  
Temple University and University of Pennsylvania

Jessica M. André and Ingrid R. Olson  
Temple University

**Objective:** There is mounting evidence that the posterior parietal cortex (PPC) plays an important role in episodic memory. We previously found that patients with PPC damage exhibit retrieval-related episodic memory deficits. Here we assess whether parietal lobe damage affects episodic memory on a different task: the Deese–Roediger–McDermott (DRM) false-memory paradigm. **Methods:** Two patients with bilateral PPC damage and a group of matched controls were tested. In Experiment 1, the task was to remember words; in Experiment 2 the task was to remember pictures of common objects. Prior studies have shown that normal participants have high levels of false memory to words, low levels to pictures. **Results:** The patients exhibited significantly lower levels of false memory to words. One patient showed significantly elevated levels of false memory to pictures. The patients' false memories were accompanied by reduced levels of recollection, as tested by a Remember/Know procedure. **Conclusions:** PPC damage causes decreased levels of false memories and an abnormal Remember/Know profile. Their false memory rate is similar to the rate exhibited by patients with medial temporal lobe damage. These results support the view that portions of the PPC play a critical role in objective and subjective aspects of recollection.

**Keywords:** false memory, subjective recollection, parietal lobe, memory retrieval, simultanagnosia

There is growing evidence that the posterior parietal cortex (PPC) plays an important role in episodic memory retrieval. Functional magnetic resonancing imaging (fMRI) studies have reported lateral and medial PPC activations across a wide range of episodic memory retrieval tasks (reviewed by Cabeza, 2008; Cabeza, Ciaramelli, Olson, & Moscovitch, 2008; Ciaramelli, Grady, & Moscovitch, 2008; Wagner, Shannon, Kahn, & Buckner, 2005; Vilberg & Rugg, 2008).

The functional involvement of the PPC in episodic memory has been verified by a small number of focal lesion studies (Berryhill, Phuong, Picasso, Cabeza, & Olson, 2007; Davidson et al., 2008; Simons, Peers, Mazuz, Berryhill, & Olson, 2010; reviewed by Olson & Berryhill, 2009). For instance, we previously tested two patients with bilateral parietal lobe damage—one patient with damage that was mostly in the inferior parietal lobe (IPL), and the other having damage extending into the superior parietal lobe—on a study examining autobiographical memory (Berryhill et al., 2007). Patients and matched controls were asked to select a memory from five designated epochs in their lifetimes and then describe the memory in as much

detail as possible. Following this free recall stage, we asked a series of specific probe questions that were aimed at elaborating on the number of details mentioned. The free recall and specific probe data were subjected to a detailed text analysis to categorize, tally, and rate the details mentioned by study participants (Levine, Svoboda, Hay, Winocur, & Moscovitch, 2002). The results demonstrated a surprising dissociation in the patients' performance between the free recall and the specific probe stages. Their freely recalled memories were significantly impoverished in terms of the number of details they referenced. In contrast, during the specific probe stage, patients responded with as much detail as did the control subjects. Because the task did not involve encoding, the patients' abnormally low performance is best characterized as a memory retrieval deficit.

In another study (Davidson et al., 2008), a patient with unilateral left PPC damage was tested in a series of tasks including the classic Deese–Roediger–McDermott (DRM) false-memory paradigm (Deese, 1959; Roediger & McDermott, 1995). In the standard DRM, participants are presented with lists of conceptually related words, and later, they are asked to perform an old/new recognition memory task. At retrieval, most participants claim to have seen or heard words that in fact had never appeared on the list ("false memories"). This occurs when the words are closely related to the core theme of the words on the learned list. It is thought that such false memories arise from automatic activation of conceptually related words, or "gist" information (Schacter & Slotnick, 2004). Such false memories are typically accompanied by a strong subjective sense of recollection. Metamemory processes operating at retrieval can also shape expectations about what true memories feel like, further modulating false memory rates.

The Davidson et al. (2008) report described a unique pattern of deficits in their unilateral PPC patient: She remembered relatively fewer items and made relatively fewer false alarms. Davidson et al. interpreted this as evidence that the patient was not activating the "gist" information associated with each semantically related list.

---

David B. Drowos and Marian Berryhill, Department of Psychology, Temple University, Philadelphia, Pennsylvania, and Center for Cognitive Neuroscience, University of Pennsylvania, Philadelphia; Jessica M. André and Ingrid R. Olson, Department of Psychology, Temple University, Philadelphia, Pennsylvania.

We thank Marianna Stark for recruiting participants, Anjan Chatterjee and Branch Coslett for providing the patient database, and David Wolk, Jason Chein, and Roberto Cabeza for helpful discussions. We would also like to thank Yonatan Mazuz for assistance in testing control participants and Cara Shay for stimulus development. This research was supported by RO1 MH071615 to Ingrid R. Olson and by NRSA NS059093 to Marian Berryhill.

Correspondence concerning this article should be addressed to Ingrid R. Olson, Department of Psychology, Temple University, 1701 North 13th Street, Philadelphia, PA 19122. E-mail: iolson@temple.edu

Davidson's patient also reported a decreased sense of subjective recollection, a finding that has been reported by two other groups using different tasks and stimuli (Ally, Simons, McKeever, Peers, & Budson, 2008; Simons et al., 2010).

It is important to point out that there are several negative findings in this small quantity of literature. For instance, three studies have reported that unilateral and bilateral parietal lobe damage has no deleterious effect on source memory accuracy (Davidson et al., 2008; Simons et al., 2010), even when the lesions overlap with regions activated by a source-memory task in an fMRI study (Simons et al., 2008). There is also evidence that unilateral parietal lobe damage has no measureable effect on item-recognition memory, such as recognition of a long series of words, pictures, or sounds (Haramati, Soroker, Dudai, & Levy, 2008).

In summary, the existing data indicate that parietal lobe damage affects episodic memory in some cases but not others. Because there have been only a small number of studies on this topic, and those that exist offer uneven evidence for parietal involvement in episodic memory, it is difficult to make informed hypotheses about the parietal lobes' functional role in episodic memory. Also, with a few exceptions, most reported findings have not been replicated. The goal of this study is to bolster the literature by replicating and extending the DRM findings reported by Davidson and colleagues.

Davidson's finding is valuable because the DRM task has been used on several different patient populations, thus allowing one to compare the effects of different focal lesions on task performance. In the present study, two patients with bilateral parietal lobe damage are tested on two different DRM tasks. After conducting our primary analyses, we conduct a brief qualitative meta-analysis in which the performance of our patients is compared with the performance of patients with medial temporal lobe (MTL) damage.

### Experiment 1: False Memory With Auditory Word Stimuli

#### Method

**Lesion patients.** Two patients, EE555 and TQ591, with bilateral parietal lobe damage were tested in this study. Both patients are

highly personable, alert, and attentive participants. They have been discussed extensively in prior studies (Berryhill & Olson, 2008; Berryhill et al., 2007); we summarize their neurological profiles here.

**Patient EE555.** EE555 is a 40-year-old former teacher with 16 years of education. In 2004, she suffered three infarcts in the watershed between the posterior and middle cerebral arteries. Her physical and perceptual symptoms are currently stable. EE555's MRI revealed symmetrical lesions in lateral aspects of the inferior parietal lobe, extending from superior aspects of the occipital lobe through the angular gyrus (Brodmann areas—BA—39) in and around inferior and middle portions of the intraparietal sulcus (IPS). Damage does not encroach into the midline (e.g., precuneus). EE555's lesions are depicted in Figure 1.

Patient EE555's primary deficit is simultanagnosia. When shown a line drawing of a visual scene, she describes parts of the picture—"there is a woman" and "I see water"—without attaining a global understanding of the scene. In line cancellation tasks, she crosses off items only at the center, ignoring peripheral items. She reports only the local elements when shown Navon letters. Language comprehension and speech fluency were unimpaired as assessed by her conversational skills and by ceiling performance on the auditory tests of the Western Aphasia Battery. She finds reading of long words or text passages impossible because of her simultanagnosia. Her eyesight is normal.

**Patient TQ591.** TQ591 is a 49-year-old former preschool assistant teacher with 15 years of education. She suffered bilateral parieto-occipital damage due to cerebral vasculitis in March 2006. TQ591's MRI revealed signs of previous subacute posterior cerebral artery infarctions. The primary lesions are in bilateral parietal regions (see Figure 1). The left parietal lesion extends into IPS (BA 39) and precuneus (BA 7). There are two right lesion sites: The inferior lesion is in superior aspects of the occipital lobe (BA 18 and 19), and the superior lesion is in the superior parietal lobe (BA 7). In both hemispheres, the lesions extend slightly into occipital (BA 19) regions and parietal white matter.

TQ591's primary deficit is simultanagnosia. When shown pictures of scenes, TQ591 is slow to describe them and complains that parts of

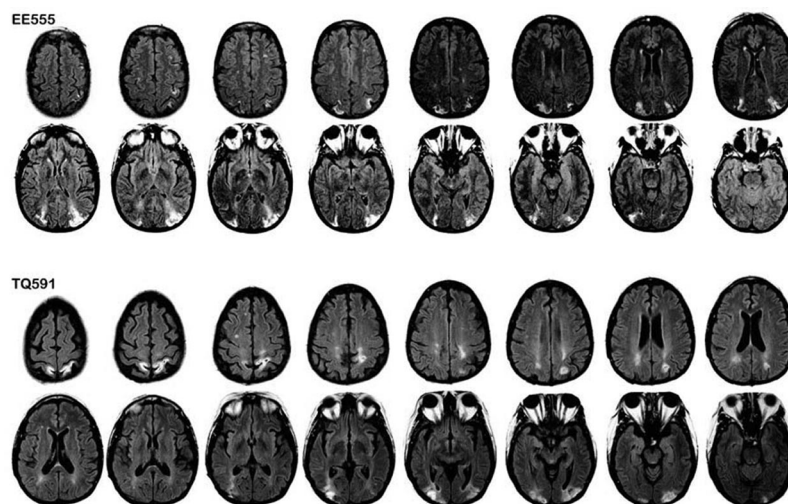


Figure 1. Patient lesion traces. Images are T2 fluid-attenuated inversion recovery (FLAIR) images in which the lesions appear as white higher-intensity patches in parietal regions. Right hemisphere is on the left side of figure.

scenes “disappear” when she looks away or blinks. In line cancellation tasks, she identifies only a few lines within a narrow visual field. She has a local bias with Navon letters. Language comprehension and speech fluency were unimpaired as assessed by her conversational skills and by ceiling performance on the auditory tests of the Western Aphasia Battery. Reading is somewhat impaired because of her simultanagnosia. Her vision is corrected to normal.

#### Neuropsychological evaluation of memory and language.

Patients were administered several standardized memory, language, and vision tests (see Table 1). First, to establish that patients are able to follow verbal instructions, we conducted auditory subtests of the Western Aphasia Battery—Revised (WAB-R; Harcourt Assessment); they both performed very well. To assess episodic and working memory, we administered auditory subtests of the Wechsler Memory Scale—III (WMS—III; The Psychological Corporation). EE555 performed at least 1 standard deviation (*SD*) below the mean on all tests, and was 2 *SD* below normal on the auditory delayed component. TQ591’s performance was in the normal range (see Table 1).

The Logical Memory I and II subtests of the WMS—III provide estimates of gist and item memory. Participants read short vignettes and then freely recalled the events immediately and later, after a lengthy delay. Performance measures evaluate gist memory on the basis of how many thematic components are retold and item memory on the basis of how many detail components are retrieved. At the immediate retelling stage, patients retold a greater proportion of the gist information than of details or item information (item vs. gist memory: EE555 = 41.3% vs. 78.3%; TQ591 = 45.3% vs. 82.6%). This pattern was also observed after the delay period (item vs. gist memory: EE555 = 36.0% vs. 86.7%; TQ591 = 36.0% vs. 73.3%).<sup>1</sup> These data indicate that gist memory was generally preserved, whereas item memory was impoverished.

As an initial assessment of parietal involvement in autobiographical memory, a standard autobiographical memory test, the Autobiographical Memory Inventory (AMI; Kopelman, Wilson, & Baddeley, 1989), was administered. This test measures memory for personal semantic and autobiographical incidents in a short-answer format. The results showed that both patients were subtly abnormal on this test.

Table 1  
*Neuropsychological Evaluation of Patients EE555 and TQ591*

Test	Subtest	EE555	TQ591
AMI	Personal semantic	49.5*	60
	Autobiographical incidents	21	17*
WMS	Immediate	86	80
	Delayed	77	97
	WM	83	79
WAB	Recognition delayed	55*	110
	Auditory verbal comprehension	60	60
	Sequential Commands	80	76
	Repetition	100	98

*Note.* The AMI Personal Semantic score is out of a total of 63 (normal = 54–63), the Autobiographical Semantic Measure is out of a total of 27 (normal = 19–27). WMS scores are index scores from auditory subtests in which the population mean is 100 and the *SD* = 15. We consider performance on the WMS abnormal if it deviates by 2 *SD*, on the AMI if it deviates from the population mean by 1 *SD*. The Western Aphasia Battery (WAB) measures were scored out of 60, 80, and 100 possible points. WM = working memory. \* Indicates abnormal scores.

EE555’s semantic recollections were scored as “probably abnormal” (see Table 1), but her description of autobiographical events was in the “acceptable” range. TQ591 showed the reverse pattern. A more complex assessment of autobiographical memory was also administered (Levine et al., 2002), and both patients performed abnormally low on free recall of life events but performed normally on cued recall (Berryhill et al., 2007). Other tests revealed that both patients exhibit visual working memory impairments when tested by old/new recognition (Berryhill & Olson, 2008).

**Control participants.** Twelve normal controls (8 men and 4 women) who were matched in age ( $M = 51.5$ , range = 39–67) and education ( $M = 14.5$ , range = 12–18) to the two patients were tested. There were no differences between patients and controls in terms of age and education ( $p > .05$ ). All control participants were given a short questionnaire to verify that they were not experiencing any neurological or psychiatric disorders at the time of testing. All participants were compensated for their participation in the experiment.

**Equipment.** Stimuli were recorded using Apple’s GarageBand software (Cupertino, CA) and were presented on a 1.83-GHz Intel Core Duo MacBook Pro laptop computer with a 15-inch monitor. Each word list was presented using iTunes software (Cupertino, CA).

**Stimuli.** The stimuli consisted of 24 digitized sound-file word lists, each containing 15 words taken from Roediger and McDermott’s (1995) work. Each list contained words that were linked through one common theme (i.e., sleep, spider, or bread), with the false alarm being the “category” of the list. A male speaker and a female speaker each spoke one half of the recordings.

**Design.** The design, depicted in Figure 2, closely followed the design of Roediger and colleagues (Roediger & McDermott, 1995). During the 45-min testing session, participants heard 16 word lists. The word lists were determined by a random number generator with an even distribution of lists spoken by male and female speakers. Immediately following the presentation of each list, the participant was asked to perform either free recall or simple arithmetic problems (i.e., addition or subtraction with whole number values ranging from 0 to 99). Use of a random number generator determined whether the free recall or simple arithmetic that followed the presentation of each list was also done. After all the word lists had been presented, a recognition test was conducted. The researcher read aloud 96 words: 3 words from each of the 16 word lists that the participant heard and the “lure” word for each list, and 3 words from the 8 word lists that the participant did not hear and the lure word for these lists as well. The participant then made an old/new judgment as to whether the word had been heard at study. If the participant made an *old* response, the participant then made a remember/know decision about the presented word. Participants were instructed to provide a *remember* response when they were able to vividly recall the word with high confidence and to make a *know* response when they had a sense of familiarity for the word but perhaps lower confidence.

**Analysis.** The same analyses were used for Experiments 1 and 2. Averages for controls were compared with patients in both free-recall and recognition tasks with  $z$  tests to determine significance ( $z > \pm 1.96 SD$ ). Corrected true recognition was calculated

<sup>1</sup> Age-standardized percentile scores were available; however, percentile ranks were not available.

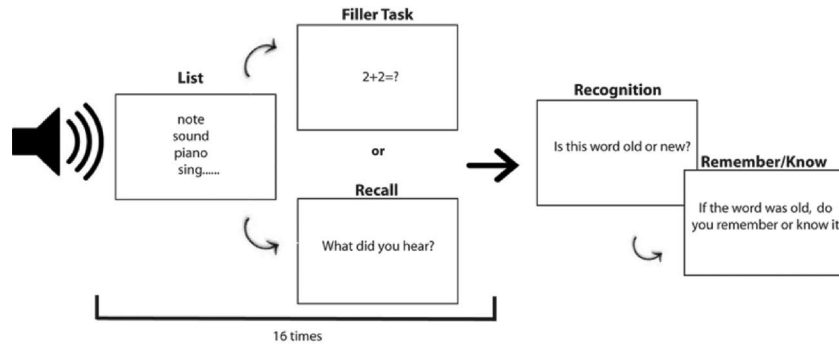


Figure 2. Schematic illustration of the Deese–Roediger–McDermott (DRM) task used in Experiment 1.

by subtracting false alarms (*old* responses to unstudied items) from hits (*old* responses to studied items; Melo, Winocur, & Moscovitch, 1999; Schacter, Verfaellie, Anes, & Racine, 1998). Corrected false recognition (CFR) scores were calculated with the following formula: CFR = hits (*old* responses to critical lures)–false alarms (*old* responses to lure controls, i.e., critical lures of unstudied lists); see Tables 2 and 3.

**Results and Discussion**

**Free recall.** In our first analysis we evaluated the free-recall portion of the task, by comparing the accuracy of control participants and patients. Although the controls correctly recalled more of the words than did the patients ( $M = .42$  vs.  $M = .33$ ), when  $z$  scores were analyzed, both patients performed within 1 *SD* of controls (EE555:  $M = .33$ ,  $z = -.78$ ; TQ591:  $M = .32$ ,  $z = -.94$ ). The rate at which participants recalled nonstudied lure words, or in other words the degree of false recall, was 44% for both controls and patients. These findings show that the patients’ DRM recall performance was normal.

**Recognition.** Recognition performance is shown in Figure 3. Patient EE555’s hit rate of 29% and false alarm rate of 38% were both abnormally low ( $z = -2.15$ ;  $z = -2.41$ ). Patient TQ591’s hit rate of 58% was in the normal range ( $z = .27$ ), but her false alarm rate of 38% was abnormally low ( $z = -2.41$ ).

We examined participants’ remember (R)/know (K) responses following each *old* response (see Figure 3). Both patients had R/K profiles resembling that of the controls for target words. However, patients’ recollection of lure words was abnormal. Patient EE555 supplied significantly fewer R responses (.50 vs. .79,  $z = -2.27$ ) than did controls. Her K responses were in the normal range. Patient TQ591 supplied significantly fewer R responses (.16 vs. .79,  $z = -3.44$ ) and significantly more K responses (.84 vs. .21,  $z = 3.54$ ) than did controls.

The results of Experiment 1 provide us with several insights into parietal lobe memory processes. The patients had normal levels of true and false memory on the recall portion of the task. However, a different picture emerges when the recognition data were assessed. One patient exhibited decreased recognition memory for target words. Both patients exhibited decreased levels of false memory, as is illustrated by their low false alarm rates, and they lacked confidence in their false memories, as is shown by their reluctance to supply remember responses. Interestingly, Patient EE555’s performance on the DRM was very similar to the performance of a patient with left PPC lesions on the DRM (Davidson et al., 2008). Davidson and colleagues (2008) attributed their patients’ deficit on the DRM to impaired memory for gist driven by a general problem with recollection.

Table 2  
Data From Experiment 1, Verbal DRM Study, Recognition Portion of the Task

Variables	Old responses			R responses			K responses		
	TQ591	EE555	Controls	TQ591	EE555	Controls	TQ591	EE555	Controls
A. Targets (heard words)	0.58	0.29*	0.63	0.61	0.64	0.70	0.39	0.36	0.30
B. Target controls (never heard words)	0.00	0.00	0.14	0.00	0.00	0.22	0.00	0.00	0.78
Corrected true recognition	0.58	0.29*	0.49	0.61	0.64	0.80	0.39	0.36	0.20
C. Critical lures (lures corresponding to heard lists)	0.38*	0.38*	0.69	0.16*	0.50*	0.72	0.84*	0.50	0.28
D. Lure controls (lures from never heard lists)	0.00	0.00	0.16	0.00	0.00	0.25	0.00	0.00	0.75
Corrected false recognition	0.38	0.38	0.53	0.16*	0.50*	0.79	0.84*	0.50	0.21

Note. This Table mimics Table 4 of Davidson et al. (2008) to allow comparison between parietal patients. Based on standard high-threshold procedures (Melo et al., 1999; D. L. Schacter et al., 1998) Corrected True Recognition (CTR) was calculated using the formula: CTR = hits (“old” responses to targets) – false alarms (“old” responses to target-controls, i.e. items from unstudied lists). Corrected False Recognition (CFR) scores were calculated with the formula: CFR = hits (“old” responses to critical lures) – false alarms (“old” responses to lure-controls, i.e., critical lures of unstudied lists). R and K responses were computed as a proportion of the old responses; thus, they do not add up to 100 vertically but do horizontally.

\*  $Z$  scores below  $-1.96$  are considered impaired.

Table 3

Data From Experiment 2, DRM Visual Study, Recognition Portion of the Task

Variables	Old responses			R response			K responses		
	TQ591	EE555	Controls	TQ591	EE555	Controls	TQ591	EE555	Controls
A. Targets (heard words)	0.79*	0.77*	0.92	0.76	0.76	0.89	0.24	0.24	0.11
B. Target controls (never heard words)	0.08	0.04	0.03	0.91	0.91	0.53	0.09	0.09	0.47
Corrected true recognition	0.71*	0.73*	0.89	0.69	0.69	0.93	0.31	0.31	0.07
C. Critical lures (lures corresponding to heard lists)	0.00	0.44*	0.19	0.00	0.44	0.78	0.00	0.56*	0.22
D. Lure controls (lures from never heard lists)	0.25	0.00	0.10	1.00	0.00	1.00	0.00	0.00	0.00
Corrected false recognition	-0.25	0.44*	0.09	1.00	0.29	0.61	0.00	0.71*	0.39

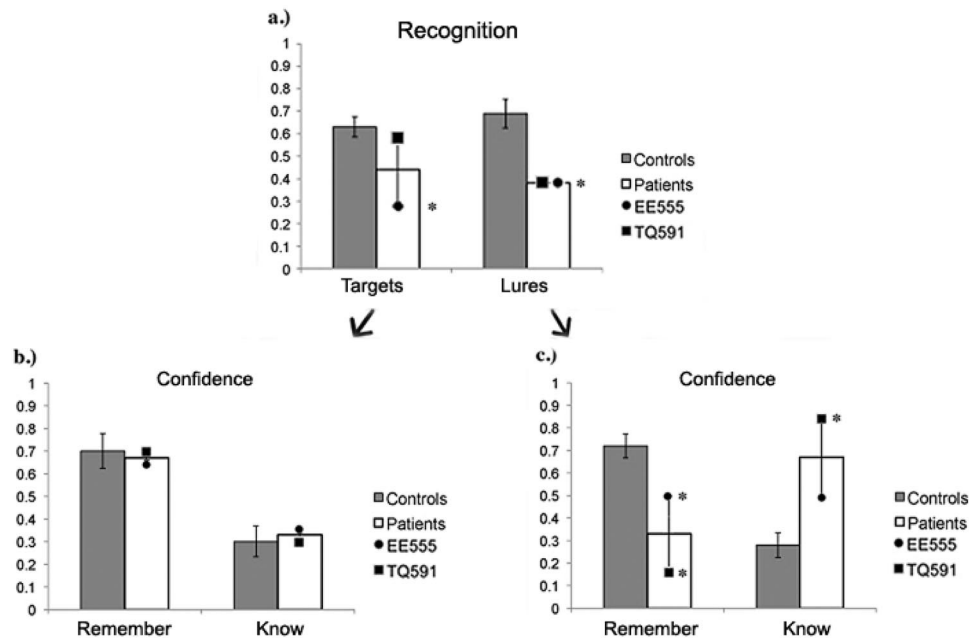
*Note.* This Table mimics Table 4 of Davidson et al. (2008) to allow comparison between parietal patients. Based on standard high-threshold procedures (Melo et al., 1999; Schacter et al., 1998). Corrected True Recognition (CTR) was calculated using the formula: CTR = hits ("old" responses to targets) - false alarms ("old" responses to target-controls, i.e. items from unstudied lists). Corrected False Recognition (CFR) scores were calculated with the formula: CFR = hits ("old" responses to critical lures) - false alarms ("old" responses to lure-controls, i.e., critical lures of unstudied lists). R and K responses were computed as a proportion of the old responses, thus they will not add up to 100 vertically but will horizontally.

\* Z Scores Below -1.96 are considered impaired.

### Experiment 2: False Memory With Visual Objects

The goal of Experiment 2 was to replicate the findings of Experiment 1 and to explore one reason for the diminished levels of false memories and recollection observed in Experiment 1. Reduced false memory rates can reflect problems at several different stages of memory (Johnson & Raye, 2000). Problems with gist extraction or gist memory, such as a failure to understand the semantic theme of a word list or a problem in retrieving the overall gist (Ciaramelli, Ghetti, Frattarelli, & Ladavas, 2006; Melo et al., 1999; Schacter et al., 1998), can decrease false memory rates. Unusually good item-specific mem-

ory or source memory can also decrease false memory rates, because subjects can accurately distinguish studied words from similar lures. Last, metamemory processes can influence criteria used to make memory decisions at retrieval. Several such processes have been documented, such as the metamemory belief that self-generated information is more memorable than is heard information (Johnson & Raye, 1981). A similar process can explain the finding that false recognition is significantly reduced by using pictorial stimuli in comparison with word stimuli (Dodson & Schacter, 2002; Israel & Schacter, 1997; Schacter, Israel, & Racine, 1999; Smith, Lozito, &



*Figure 3.* Results from (a) the recognition portion of the Deese-Roediger-McDermott (DRM) task used in Experiment 1; (b) remember/know (R/K) responses to targets; and (c) R/K responses to lures. Data are raw accuracy for targets and lures. Each patient's mean accuracy is illustrated by a symbol overlaid on the column. Error bars represent the standard error of the mean. The asterisks denote a significant difference between patient and control performance.

Bayen, 2005). This effect may be due to differences between the semantic associations of words and pictures, pictures that have a smaller semantic network, or a metamemory belief termed the *distinctiveness heuristic* (e.g., Israel & Schacter, 1997; Schacter et al., 1999), in which individuals expect to remember distinctive information after picture encoding. The distinctiveness heuristic is thus a strategy that normal participants adopt with which the failure to remember expected information, in this case, distinctive image-based information, signals that the event did not occur. As such, the use of pictures in a DRM paradigm tends to make normal participants more conservative, because they tend to rely heavily on item-specific recollection to reject lures.

In Experiment 2 we assessed whether parietal lobe damage affects the ability to use distinctiveness to modulate false recognition. If found, it would suggest that parietal lobe damage affects recollection, the strategic use of distinctive information, or both.

## Method

**Lesion patients.** The same patients tested in Experiment 1 were tested.

**Control participants.** Twelve normal controls (7 men and 5 women) who were matched to the patient in age ( $M = 49$ , range = 37–66) and education ( $M = 14$ , range = 12–16) were tested. There were no differences between patient and controls in terms of age and education (both  $ps > .05$ ). All control participants were given a short questionnaire to verify that they were not experiencing any neurological or psychiatric disorders at the time of testing. All participants were compensated for their participation in the experiment.

**Equipment.** Stimuli were presented on a 2.39-GHz Intel Core Duo Dell Optiplex 745, and we utilized a 22-inch Viewsonic 2245 monitor for display of images. All stimuli were presented using E-Prime 2.0 (Psychology Software Tools, Pittsburgh, PA).

**Stimuli.** The stimuli consisted of 24 picture lists, each containing 15 pictures that were semantically related. Each list contained pictures that were linked through one common theme (i.e., baby, clown, or school), with the false alarm being the “category” of the list (see the Appendix). Picture stimuli consisted of color photographs of real objects. Pictures were manipulated in Adobe Photoshop to make them approximately the same size, about  $200 \times 200$  pixels.

**Design.** The design closely followed the design of Experiment 1 with the one exception of presenting picture lists instead of auditory word lists. The 45-min testing session consisted of three parts: picture encoding, recall testing, and recognition testing. Part 1 began with the presentation of 16 of the 24 picture lists. Different participants were shown different lists during the testing session, following an order determined by a random number generator. Each picture was presented for 1500 ms, followed by a 700-ms interstimulus interval (ISI).

At the end of each 15-item list, one of two things happened with equal likelihood in pseudorandom order. On one half of trials, participants were required to perform a free-recall memory task in which they listed all of the items that they had just seen. On the other half of trials, they were given simple arithmetic problems consisting of addition or subtraction with whole number values ranging from 0 to 99. The presentation of another 15-item picture list was then presented for encoding. This continued until all 16 picture lists had been presented.

After all the picture lists had been presented, a surprise recognition test was administered. Ninety-six pictures were presented: 3 pictures from each of the 16 picture lists that the participant had previously seen and the lure picture for each list, and 3 pictures from the 8 picture lists that the participant had not seen and the lure pictures from the unseen lists as well. Each picture was presented for 1500 ms and followed by a 700-ms ISI. The task was to make an old/new judgment as to whether the picture had previously been seen or not. If the participant selected *old*, a remember/know decision about the presented picture was elicited. Participants were instructed to provide a *remember* response when they were able to vividly recall the picture and to make a *know* response when they had a sense of familiarity for the picture.

## Results and Discussion

**Free recall.** In our first analysis, we evaluated performance on the free-recall portion of the task by comparing the accuracy of control participants with that of each patient. Patient EE555 recalled significantly fewer pictures (control  $M = .51$ , EE555  $M = .32$ ,  $z = -2.02$ ), but patient TQ591 was not significantly impaired ( $M = .48$ ,  $z = -.38$ ). We also assessed the rate at which participants recalled nonstudied lure items, in other words, the degree of false recall. Again, Patient EE555 performed abnormally by recalling significantly more lure items than did control subjects (controls  $M = .13$ , EE555  $M = .38$ ,  $z = 1.79$ ). Patient TQ591 performed no differently than did controls (TQ591  $M = .13$ ,  $z = 0$ ). The patients made few wrong responses or intrusions (3 intrusions each), but across all control participants there were only a total of 11 intrusions. The results of the recall analysis indicate that Patient EE555 had diminished free recall but elevated false recall of pictures, whereas Patient TQ591 performed within the normal range on both measures.

**Recognition.** Recognition performance is shown in Figure 4 and detailed in Table 3. Patient EE555’s hit rate of 77% and false alarm rate of 44% were both abnormal, similar to the findings reported in Experiment 1 ( $M$  controls = 92%,  $z = -2.36$ ;  $M$  controls = 19%,  $z = -1.96$ ). In this case, however, her false alarm rate was significantly higher than that of controls. Patient TQ591’s hit rate of 79% was also abnormally low ( $z = -2.02$ ). She had a low false alarm rate of 0%, which was numerically lower than that of controls. However, the low false alarm rate of the control participants hampered our ability to detect a statistical difference in Patient TQ591 ( $z = -1.46$ ).

As was noted earlier, prior studies have shown that normal adults tend to exhibit relatively low levels of false recognition for pictorial stimuli in comparison with verbal stimuli. This finding was apparent in our data: The corrected false recognition rate of normal controls dropped significantly between Experiment 1 and Experiment 2 (Experiment 1  $M = .53$ ; Experiment 2  $M = .08$ ,  $t(22) = 6.56$ ;  $p < .0004$ ). This improvement in corrected false recognition was observed in Patient TQ591, but it was not observed in Patient EE555. However, both patients were better able to discriminate between old and new items in Experiment 2 than in Experiment 1, as was indicated by the larger difference between their corrected true and false recognition scores (Experiment 1  $M = .06$ , Experiment 2  $M = .38$ ).

The overall pattern for R/K responses to the lure items was similar to what was observed in Experiment 1 (see Figure 4). Patients exhibited normal levels of recollection for old items; their R/K distributions for lures was more interesting. Patient EE555’s

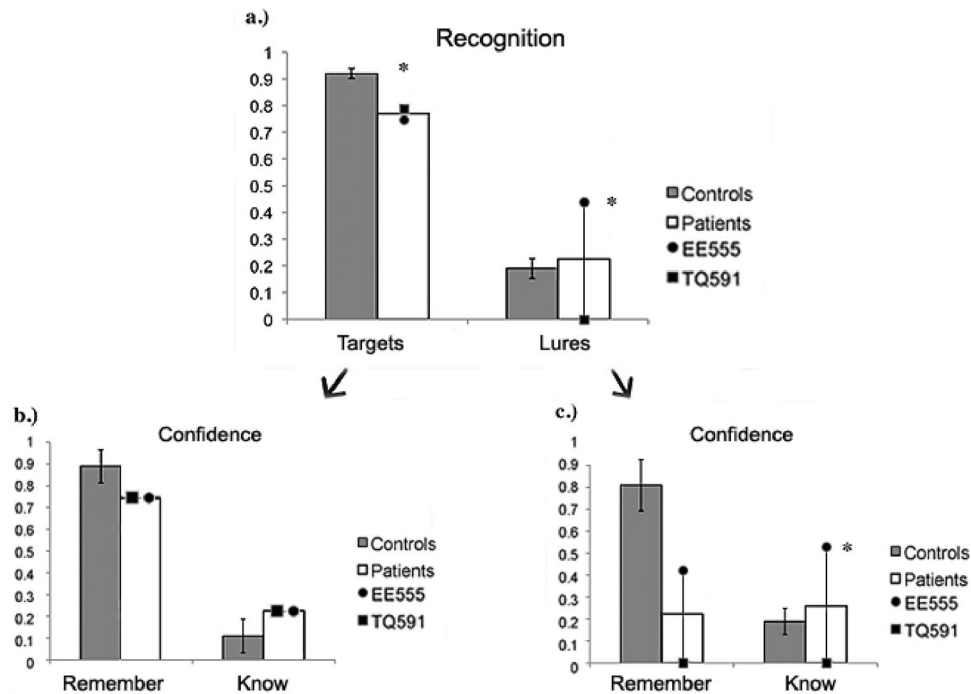


Figure 4. Results from (a) the recognition portion of the visual Deese–Roediger–McDermott (DRM) task used in Experiment 2; (b) remember/know (R/K) responses to targets; and (c) R/K responses to lures. Data are raw accuracy for targets and lures. Error bars represent the standard error of the mean. The asterisks denote a significant difference between patient and control performance.

R/K profile was dominated by *know* responses (control  $M = .39$ , EE555  $M = .71$ ,  $z = 2.70$ ), with a numerically lower number of *remember* responses in relation to those of controls (control  $M = .61$ , EE555  $M = .29$ ,  $z = -.77$ ). Patient TQ591's R/K profile was impossible to assess because she made only two false alarms to lure control items and none to lure items.

In summary, the results of Experiment 2 show that Patient EE555 had lower levels of true memory on both the recall and the recognition portions of the task. Unlike control participants, she failed to benefit from distinctiveness and thus showed an elevated false recognition rate. Her false recognition responses were characterized by reduced recollection. In contrast, Patient TQ591 performed relatively normally on the recall portion and somewhat abnormally on the recognition portion of the task. Her false recall and recognition scores were normal.

These results suggest that Patient EE555 failed to adopt a normal metamemory strategy that would allow one to benefit from item-specific recollection processes that tend to accompany pictorial stimuli. Alternatively, EE555's memory for pictorial stimuli may have been so impoverished in detail that even if a conservative response strategy were adopted, the quality of the remembered information was insufficient to support its implementation. The second alternative is supported by the finding that she had abnormally low levels of true memories as assessed by both recall and recognition. As in Experiment 1, EE555 lacked confidence in her false memories. In contrast, Patient TQ591 appeared to benefit from the pictorial stimuli, and although she was less accurate at recognizing previously seen pictures, she was not prone to making false alarms.

## General Discussion

It is well known that our recollection of the past is not a veridical simulacrum of what we have experienced but rather is a flawed recreation of bygone events. The flaws in our memory are such that people frequently claim to have seen or heard something never experienced, a phenomenon captured by false memory tasks. False memories are thought to arise when target words cause the automatic activation of semantically and conceptually related gist information (Schacter, Verfaellie, & Koutstaal, 2002), leading to a false sense of recollection. In this study we used a standard false memory task, the DRM, to ask whether the parietal lobe plays any meaningful role in true memories and false memories.

Experiment 1 used a classic DRM task with auditorily presented verbal stimuli. Two patients with bilateral parietal lobe damage were tested. Both patients exhibited normal levels of word recall after relatively short delays. The recognition task occurred after a longer delay period. One of the patients, EE555, had decreased levels of true memory on the recognition task. Nevertheless, both she and the second patient exhibited normal levels of confidence in their old responses. A different picture emerged when the lure trials were examined. Both patients exhibited low numbers of false memories, and their false memories were accompanied by few reports of recollection as measured by their R/K profile. For example, Patient TQ591 gave *remember* responses to lures only 16% of the time, and the normal control participants gave *remember* responses to lures 72% of the time.

In Experiment 2, we tested a variant of the classic verbal DRM in which the stimuli were pictures rather than words. Prior studies

of normal adults have found that false recognition is significantly reduced by using pictorial stimuli rather than word stimuli (Israel & Schacter, 1997; Schacter et al., 1999). Both patients were more accurate when recognizing target pictures than when remembering words. However, the patients' false recognition rates differed. Patient EE555's false recognition rates remained constant across both experiments, suggesting that she did not benefit from the distinctiveness heuristic. Furthermore, her false memories were accompanied by an abnormal R/K profile, causing her to have a statistically lower level of confidence on the lure trials. In contrast, TQ591's false recognition rate decreased, suggesting that she did benefit from the distinctiveness heuristic, similarly to controls.

It is important to emphasize that the observed deficits do not appear to be linked to the patients' perceptual deficits—such as difficulty perceiving spatial information, especially information that is spatially arrayed, such as a visual scene. The stimuli used in Experiment 1 were auditory words without meaningful spatial attributes. The stimuli used in Experiment 2 were single common objects presented at central fixation, which were easily perceived by all participants. We have shown in the past that the patients tested here do not have global mental imagery impairments (Berryhill et al., 2007), so it is unlikely the case that deficient mental imagery problems account for these findings. As such, we turn to mnemonic explanations for our findings.

### Parietal Lobe Memory Mechanisms

There is fMRI evidence linking parietal lobe activity to both episodic memory encoding and retrieval. In the former case, subsequent memory paradigms have shown encoding-related activity in the inferior parietal lobe that predicts poor memory retrieval, whereas more superior lateral parietal activity predicted good memory retrieval (Uncapher & Wagner, 2009). Other fMRI findings strongly indicate that inferior and superior aspects of the parietal lobe play distinct roles in memory retrieval (Cabeza et al., 2008).

False memories can arise from many sources, including the activation at encoding of overlapping representations that lead to the formation of a strong gist representation due to semantic relatedness (e.g., Brainerd, Yang, Reyna, Howe, & Mills, 2008) or associative strength (e.g., Roediger, Watson, McDermott, & Gallo, 2001). However, it is difficult to explain the abnormal false memory rates in Experiment 1 as a problem specific to gist encoding. Memory for the thematic content of stories, a form of gist, was specifically tested in the WMS-III. The results showed that the patients' memory for the gist of short stories was normal but that their item-specific memory was abnormal (see Experiment 1, Method section). Of course, it is possible that our patients can extract gist from stories, which are context rich, while failing to activate semantic associates from single words, but here, too, we have observed normal levels of semantic priming on an implicit priming task, indicating that these patients have normal access to semantic associates. Although the possibility remains that parietal lobe memory deficits arise at encoding, the neuropsychological data that we have collected to date do not support this contention.

Instead, our findings tend to favor a retrieval account. It is well known that abnormal false memory rates can reflect problems at retrieval (Johnson & Raye, 2000). For instance, metamemory processes operating at retrieval bias expectations about what true memories feel like, thus modulating false memory rates. Also, the

amount of retrieved perceptual detail modulates subjective memory states (Johnson & Raye, 2000).

The subjective feeling of fully reexperiencing or recollecting the event typically accompany *remember* responses (Tulving, 1985). Many studies, including our own, have shown that normal individuals experience false memories accompanied by strong feelings of recollection, as is indicated by a high number of *remember* responses. The bilateral PPC patients experienced false memories accompanied by weak feelings of recollection. This behavior should not be perceived as a general outcome of brain damage, however. Both patients had normal levels of recollection to the target words in Experiment 1. Also, in three source memory tasks in which confidence ratings were collected, the same patients had normal levels of confidence for old/new recognition judgments but abnormally low levels of confidence when making source memory judgments (Simons et al., 2010).

The issue of memory confidence has typically been conceived of as inherently intertwined with the process of remembering: High confidence responses (to targets) are thought to accompany recollection, whereas low confidence responses are thought to mainly accompany familiarity. Another possibility is that these processes are different facets of memory, with only subjective aspects of memory being linked to IPL function (Ciaramelli, Lin, & Moscovitch, 2009). This observation is based on the fact that several studies have reported intact source recollection accompanied by depressed subjective memory states after parietal lobe damage (Davidson et al., 2008; Simons et al., 2008, 2010). There are several possible explanations for the patients' decreased subjective memory states. One possibility is that the parietal lobe may be involved in recollecting perceptual details. Consequently, when the parietal lobe is damaged, the memory lacks detail and leads to reduced memory confidence (Johnson & Raye, 2000). Alternatively, the parietal lobe may also play a role in bottom-up internal attention. This type of attention may be required for memory retrieval. Parietal lesions may impair the automatic retrieval of memories, and because memory retrieval is less spontaneous, the patient's recollection, or sense of reexperiencing the memory, is lowered (Cabeza, 2008; Cabeza et al., 2008).

### Relationship to fMRI Findings

The present findings have some concordance with neuroimaging findings. A robust finding within neuroimaging is the "old/new effect" (reviewed by Wagner et al., 2005). This effect refers to the observation that in memory paradigms, increased parietal activity is observed whenever an item is endorsed as "old," even when that response is incorrect. This finding supports the view that parietal structures are involved in providing a signal corresponding to perceived oldness. The prediction from these findings is that parietal damage should decrease patient's ability to assess perceived oldness. Also, fMRI studies have frequently reported that superior PPC activations correlate with familiarity and low-confidence responses, whereas inferior PPC activations correlate with recollection and high-confidence responses (reviewed by Cabeza et al., 2008; Vilberg & Rugg, 2008). In the DRM task, responses to targets are thought to reflect some combination of recollection and familiarity, whereas responses to lures mostly reflect familiarity. The fMRI findings thus predict that inferior PPC damage should decrease recollection (hits) and high-confidence responses (*remember* responses). In line with this, Patient EE555 had significantly lower memory for target words and pictures mostly owing

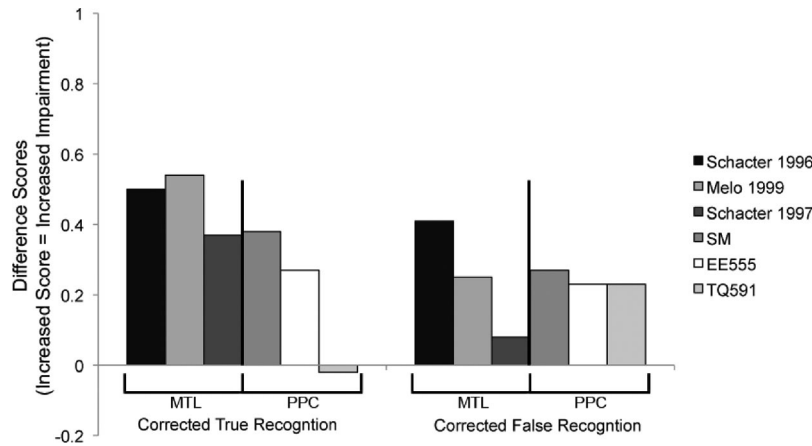


Figure 5. Review of focal lesion studies of the standard verbal Deese–Roediger–McDermott (DRM). Each bar shows the difference scores (control performance minus patient performance) for corrected true and false recognition for medial temporal lobe (MTL) lesion patients (Melo et al., 1999; Schacter et al., 1996, 1997) or for posterior parietal cortex (PPC) lesion patients (Patient SM from Davidson et al., 2008; this article). Higher bars indicate worse performance.

to a reluctance to supply old responses. Also, her R/K profile on lure trials was dominated by low-confidence *know* responses.

### Comparison to Other Patient Populations

The cognitive neuroscience of false memory has concentrated on two brain areas: the lateral frontal lobe and the medial temporal lobe (MTL). Patients with focal lateral frontal lobe lesions perform more variably on an array of false memory paradigms, but generally have elevated levels of false recognition (Budson, Daffner, Desikan, & Schacter, 2000; Budson et al., 2002; Curran, Schacter, Norman, & Galluccio, 1997; Parkin, Ward, Bindschaedler, Squires, & Powell, 1999; Schacter, Curran, Galluccio, Milberg, & Bates, 1996; Stuss & Levine, 2002), whereas patients with hippocampal or diencephalic lesions tend to show abnormally low levels of false memories (for a review, see Schacter et al., 2002). Similarly, patients with Alzheimer's disease who possess some combination of hippocampal and frontal lobe pathology tend to exhibit diminished levels of both true and false recognition (Balota et al., 1999; Budson et al., 2002), which has variably been attributed to impoverished gist memory or lack of item-specific recollection. This can be contrasted to normal aging in which there is a reduced tendency to accurately retrieve target words, but an increased tendency to erroneously retrieve lure words (Balota et al., 1999).

Only one other study has examined true and false memory in patients with parietal lobe damage. Davidson and colleagues (2008) tested one patient with unilateral left parietal lobe damage on a verbal DRM task and found that false recognition was significantly decreased, similar to the findings reported in Experiment 1. Davidson's (2008) findings indicate that the left PPC, more than the right, may be critical for normal performance on the standard (verbal) DRM.

One shortcoming of our study is that a lesion-control population was not tested. Perhaps the most interesting comparison group would be with patients sustaining bilateral MTL damage, because they also exhibit diminished true and false memory. To compare the magnitude of the effect observed in those patients to the effects reported in PPC patients, we plotted difference scores—performance of matched controls minus patients—in Figure 5. Only

studies that used the identical DRM task—the standard verbal version—were included in order to constrain stimulus and task differences. Figure 5 shows that the magnitude of the false memory impairment exhibited by both of our patients is of a similar magnitude to Davidson et al.'s (2008) patient and to the MTL patients tested by one group, that of Melo et al. (1999). In the future it will be important to directly compare the performance of patients with PPC damage to patients with medial temporal and frontal lobe pathology in order to determine the relative contribution of each region to true and false recognition.

As with any experimental methodology, there are inherent limitations; neuropsychological research is no exception. In this study, we tested a small number of bilateral PPC patients because of their scarcity. The issue of small sample size is a frequent limitation in lesion studies, particularly when a rare patient group is studied. Other limitations associated with neuropsychological research include the likelihood of postinsult brain reorganization, the possibility of damage to other brain structures that remains invisible or unnoticed, and patients' use of different strategies to perform cognitive tasks. However, the current findings can serve as a useful guide when interpreting data from other sources such as the powerful, but correlational, method of functional neuroimaging.

### References

- Ally, B. A., Simons, J. S., McKeever, J. D., Peers, P. V., & Budson, A. E. (2008). Parietal contributions to recollection: Electrophysiological evidence from aging and patients with parietal lesions. *Neuropsychologia*, *46*(7), 1800–1812.
- Balota, D. A., Cortese, M. J., Duchek, J. M., Adams, D., Roediger, H. L., III, McDermott, K. B., & Yerys, B. E. (1999). Veridical and false memories in healthy older adults and in dementia of the alzheimer's type. *Cognitive Neuropsychology*, *16*, 361–384.
- Berryhill, M. E., & Olson, I. R. (2008). The right parietal lobe is critical for working memory. *Neuropsychologia*, *46*(7), 1767–1774.
- Berryhill, M. E., Phuong, L., Picasso, L., Cabeza, R., & Olson, I. R. (2007). Parietal lobe and episodic memory: Bilateral damage causes impaired free recall of autobiographical memory. *Journal of Neuroscience*, *27*, 14,415–14,423.

- Brainerd, C. J., Yang, Y., Reyna, V. F., Howe, M. L., & Mills, B. A. (2008). Semantic processing in "associative" false memory. *Psychonomic Bulletin & Review*, *15*(6), 1035–1053.
- Budson, A. E., Daffner, K. R., Desikan, R., & Schacter, D. L. (2000). When false recognition is unopposed by true recognition: Gist-based memory distortion in Alzheimer's disease. *Neuropsychology*, *14*(2), 277–287.
- Budson, A. E., Sullivan, A. L., Mayer, E., Daffner, K. R., Black, P. M., & Schacter, D. L. (2002). Suppression of false recognition in Alzheimer's disease and in patients with frontal lobe lesions. *Brain*, *125*(12), 2750–2765.
- Cabeza, R. (2008). Role of parietal regions in episodic memory retrieval: The dual attentional processes hypothesis. *Neuropsychologia*, *46*(7), 1813–1827.
- Cabeza, R., Ciaramelli, E., Olson, I. R., & Moscovitch, M. (2008). The parietal cortex and episodic memory: An attentional account. *Nature Reviews Neuroscience*, *9*, 613–625.
- Ciaramelli, E., Ghetti, S., Frattarelli, M., & Ladavas, E. (2006). When true memory availability promotes false memory: Evidence from confabulating patients. *Neuropsychologia*, *44*, 1866–1877.
- Ciaramelli, E., Grady, C. L., & Moscovitch, M. (2008). Top-down and bottom-up attention to memory: A hypothesis (AtoM) on the role of the posterior parietal cortex in memory retrieval. *Neuropsychologia*, *46*, 1828–1851.
- Ciaramelli, E., Lin, O., & Moscovitch, M. (2009). Episodic memory for spatial context biases spatial attention. *Experimental Brain Research*, *192*(3), 511–520.
- Curran, T., Schacter, D. L., Norman, K. A., & Galluccio, L. (1997). False recognition after a right frontal lobe infarction: Memory for general and specific information. *Neuropsychologia*, *35*(7), 1035–1049.
- Davidson, P. S. R., Anaki, D., Ciaramelli, E., Cohn, M., Kim, A. S. N., Murphy, K. J., . . . , Levine, B. (2008). Does parietal cortex support episodic memory? Evidence from focal lesion patients. *Neuropsychologia*, *46*(7), 1743–1755.
- Deese, J. (1959). On the prediction of occurrence of particular verbal intrusions in immediate recall. *Journal of Experimental Psychology*, *58*, 17–22.
- Dodson, C. S., & Schacter, D. L. (2002). Aging and strategic retrieval processes: Reducing false memories with a distinctiveness heuristic. *Psychology and Aging*, *17*, 405–415.
- Haramati, S., Soroker, N., Dudai, Y., & Levy, D. A. (2008). The posterior parietal cortex in recognition memory: A neuropsychological study. *Neuropsychologia*, *46*(7), 1756–1766. doi:10.1016/j.neuropsychologia.2007.11.015
- Israel, L., & Schacter, D. L. (1997). Pictorial encoding reduces false recognition of semantic associates. *Psychonomic Bulletin & Review*, *4*(4), 577–581.
- Johnson, M. K., & Raye, C. L. (1981). Reality monitoring. *Psychological Review*, *88*, 67–85.
- Johnson, M. K., & Raye, C. L. (2000). Cognitive and brain mechanisms of false memories and beliefs. In I. D. L. S. E. Scarry (Ed.), *Memory, brain, and belief* (pp. 35–86). Cambridge, MA: Harvard University Press.
- Kertesz, A. (1982). *The Western Aphasia Battery*. New York, NY: Grune & Stratton.
- Kopelman, M. D., Wilson, B. A., & Baddeley, A. D. (1989). The autobiographical memory interview: A new assessment of autobiographical and personal semantic memory in amnesic patients. *Journal of Clinical and Experimental Neuropsychology*, *11*(5), 724–744.
- Levine, B., Svoboda, E., Hay, J. F., Winocur, G., & Moscovitch, M. (2002). Aging and autobiographical memory: Dissociating episodic from semantic retrieval. *Psychology and Aging*, *17*, 677–689.
- Melo, B., Winocur, G., & Moscovitch, M. (1999). False recall and false recognition: An examination of the effects of selective and combined lesions to the medial temporal lobe/diencephalon and frontal lobe structures. *Cognitive Neuropsychology*, *16*, 343–359.
- Olson, I. R., & Berryhill, M. E. (2009). Some surprising findings on the involvement of the parietal lobe in human memory. *Neurobiology of Learning and Memory*, *91*, 155–165.
- Parkin, A. J., Ward, J., Bindschaedler, C., Squires, E. J., & Powell, G. (1999). False recognition following frontal lobe damage: The role of encoding factors. *Cognitive Neuropsychology*, *16*, 243–265.
- Roediger, H. L., III, & McDermott, K. B. (1995). Creating false memories: Remembering words not presented in lists. *Journal of Experimental Psychology: Learning, Memory, and Cognition*, *21*, 803–814.
- Roediger, H. L., III, Watson, J. M., McDermott, K. B., & Gallo, D. A. (2001). Factors that determine false recall: A multiple regression analysis. *Psychonomic Bulletin & Review*, *8*(3), 385–407.
- Schacter, D. L., Curran, T., Galluccio, L., Milberg, W. P., & Bates, J. F. (1996). False recognition and the right frontal lobe: A case study. *Neuropsychologia*, *34*(8), 793–808.
- Schacter, D. L., Israel, L., & Racine, C. (1999). Suppressing false recognition in younger and older adults: The distinctiveness heuristic. *Journal of Memory and Language*, *40*(1), 1–24.
- Schacter, D. L., & Slotnick, S. D. (2004). The cognitive neuroscience of memory distortion. *Neuron*, *44*, 149–160.
- Schacter, D. L., Verfaellie, M., & Anes, M. D. (1997). Illusory memories in amnesic patients: Conceptual and perceptual false recognition. *Neuropsychology*, *11*(3), 331–342.
- Schacter, D. L., Verfaellie, M., Anes, M. D., & Racine, C. (1998). When true recognition suppresses false recognition: Evidence from amnesic patients. *Journal of Cognitive Neuroscience*, *10*, 668–679.
- Schacter, D. L., Verfaellie, M., & Koutstaal, W. (2002). Memory illusions in amnesic patients: Findings and implications. In L. Squire & D. L. Schacter (Eds.), *Neuropsychology of memory* (pp. 114–129). New York, NY: Guilford Press.
- Simons, J. S., Peers, P. V., Hwang, D. Y., Ally, B. A., Fletcher, P. C., & Budson, A. E. (2008). Is the parietal lobe necessary for recollection in humans? *Neuropsychologia*, *46*(4), 1185–1191.
- Simons, J. S., Peers, P. V., Mazur, Y., Berryhill, M. E., & Olson, I. R. (2010). Dissociation between memory accuracy and memory confidence following bilateral parietal lesions. *Cerebral Cortex*, *20*, 479–485.
- Smith, R. E., Lozito, J., & Bayen, U. J. (2005). Adult age differences in distinctive processing: The modality effect in false recall. *Psychology and Aging*, *20*, 486–492.
- Stuss, D. T., & Levine, B. (2002). Adult clinical neuropsychology: Lessons from studies of the frontal lobes. *Annual Review of Psychology*, *53*, 401–433.
- Tulving, E. (1985). *Elements of episodic memory*. New York, NY: Oxford University Press.
- Uncapher, M. R., & Wagner, A. D. (2009). Posterior parietal cortex and episodic encoding: Insights from fMRI subsequent memory effects and dual-attention theory. *Neurobiology of Learning and Memory*, *91*(2), 139–154.
- Vilberg, K. L., & Rugg, M. D. (2008). Memory retrieval and the parietal cortex: A review of evidence from event-related fMRI. *Neuropsychologia*, *46*, 1787–1799.
- Wagner, A. D., Shannon, B. J., Kahn, I., & Buckner, R. J. (2005). Parietal lobe contributions to episodic memory retrieval. *Trends in Cognitive Neuroscience*, *9*, 9.
- Wechsler, D. (1997). *WMS-III Administration and Scoring Manual*. San Antonio, TX: The Psychological Corporation.

## Appendix

Stapler	Car	Refrigerator	Clown	Hammer	Baseball	Dog	School
Pen	Train	Fork	Trapeze	Nail	Diamond	Bone	Desk
Pencil	Segway	Peeler	Cotton Candy	Screwdriver	Base	Rabbit	Teacher
Pencil Sharpener	Tractor	Knife	(Big Top) Tent	Toolbox	Pitcher	Cat	Chalkboard
Tape	Helicopter	Spoon	Elephant	Saw	Catcher	Frisbee	Microscope
Scissors	Traffic Light	Mixer	Balloon Animal	Tape Measure	Hotdog	Wolf	Calculator
Paperclip	Hot Air Balloon	Plate	Clown Car	Level	Cracker Jacks	Bowl	Locker
Ruler	Submarine	Stove	Juggler	Axe	Bat	Fleas	Apple
Highlighter	Bicycle	Oven Mitt	Tightrope	Drill	Glove	Collar	Eraser
Filing Cabinet	Motorcycle	Microwave	Ringmaster	Mallet	Umpire	Leash	Notebook
Desk	Truck	Pan	Bozo Shoes	Wrench	Scoreboard	Dog House	Bus
Clipboard	Tricycle	Pot	Peanuts	Pliers	Stadium	Paw (Print)	Backpack
Rolledex	Bus	Blender	Unicycle	Socket Wrench	Cards	Bed	Crayon
Briefcase	Buggy	Coffee Pot	Wig	Crowbar	Helmet	Kibbles & Bits	Hopsotch
Scanner	Scooter	Colander	Acrobat	Ladder	Cleats	Lint Roller	Lunchbox
Office Chair	Skateboard	Faucet (Sink)	Bear	Vice	Cap	Pooper Scooper	Bell
Baby	Computer	Lion	Bird	Rose	Butterfly	Priest	Shell
Stork	CD	Rhinoceros	Worm	Daisy	Grasshopper	Church	Starfish
Bottle	Copier	Tiger	Binoculars	Violet	Bee	Bible	Volleyball
Balloons	Fax Machine	Africa	Beak	Leaf	(Insect) Wings	Angel	Bikini
Rattle	Floppy Disk	Savannah	Wing	Plant	Beatle	Jesus	Beach Chair
Safety pin (Rocking) Chair	Joystick	Camera	Talon	Stem	Jar	Star (of David)	Sunglasses
High Chair	Keyboard	Hyena	Nest	Soil	Net	Cross	Pail
Diapers	Power Strip	Hippopotamus	Eggs	Tree	Fly	Dove	Sandastle
Doll	Mouse	Antelope	Feather	Petal	Cocoon	Nun	Lighthouse
Stroller	Monitor	Joshua Tree	Bath	Tulip	Dragonfly	Wafer	Flippers
Bib	Speakers	Alligator	Cage	Vase	Caterpillar	Pope	Scuba Mask
Pacifier	Cables	Zebra	Food	Bouquet	Spider	Pipe Organ	Seagull
Crib	Apple Symbol	King	Sylvester the Cat	Pot	Ladybug	Wine Cup (Chalice)	Sandal
Mobile	Windows Symbol	Canoe	Cucu Clock	Watering Can	Mosquito	Altar	Palm tree
Teddy Bear	Processor/chip	Flashlight	South (Direction)	Roots	Peacock	Candles	Kite
Hotel	Webcam	Monkey	Flying V	Seed	Tinkerbell (fairy)	Holy Water	Sailboat
Bed	Tire	Film	Whiskey	Shirt	Earth	Cigarette	Airplane
Toiletries	Rearview mirror	Popcorn	Beer Mug	Socks	Asteroid	Smoke	Pilot
Phonebook	Steering wheel	Candy	Martini	Sweater	Moon	Doctor	Flight Attendant
Maid	Gearshift	Ticket	Police men	Pants	Astronaut	Pipe	Cockpit
Bellboy	Emergency Brake	Seat	Flask	Bra	Telescope	Red Bull can	Luggage
Suitcase	Windshield Wiper	Screen	Grey Goose	Belt	Galaxy	No Smoking Sign	Baggage Claim
Do not disturb tag	Brake Light	Usher	Absolut	Scarf	Comet	Matches	Wing
Mints (on pillow)	Door	Arcade Game	Beer (Miller Lite)	Shorts	Globe	Pills	Tray Table
Towels	Odometer	Clacker	Shot (glass)	Boots	Spaceship	Ashtray	Plane Seat
Bathrobe	Radio	Camera	Pub	Dress	Satellite	Marlboro Logo	Parachute
Slippers	Gas Pedal	Stagelights	Slot Machine	Cowboy Hat	Sun	Cigar	Life Jacket
Room service tray	Glove Compartment	Stage	Bourbon	Gloves	Constellation	Joe the Camel	Lavatory/bathroom
Minibar	Headlight	Microphone	Tequilla	Jacket	Saturn	Lighter	Propeller
Pool	Car key	Ticket Booth	Cognac	Overalls	Star	Lungs	Seatbelt
Doorman	Sun Roof	Theater	Wine (Glass)	Shoe	Rocket	Needle	Oxygen Mask
	Sideview	Mirror	Barrel	Tie	Mars	Convenience Store	Runway
		Director's Chair					

Received April 2, 2009  
Revision received November 17, 2009  
Accepted November 18, 2009 ■